

# Painful heel

**Jerzy K Pawlak**

MBBS, MSc, PhD, is a general practitioner, Winnipeg, Canada.

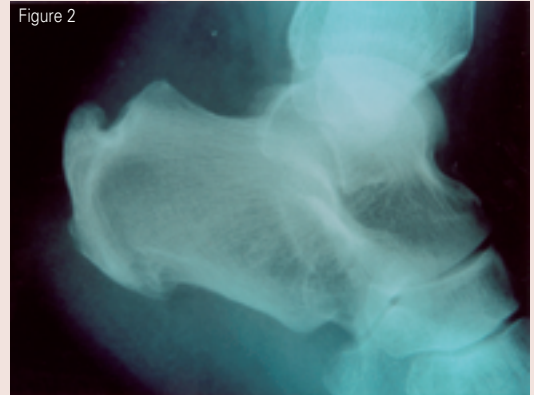
**Case history**

Betty B, 57 years of age, presented complaining of pain at the back of her left foot when walking and wearing shoes. On examination she had slight swelling and redness of the posterior heel superficial to the Achilles tendon and was tender to palpation in this area (*Figure 1*).

Figure 1

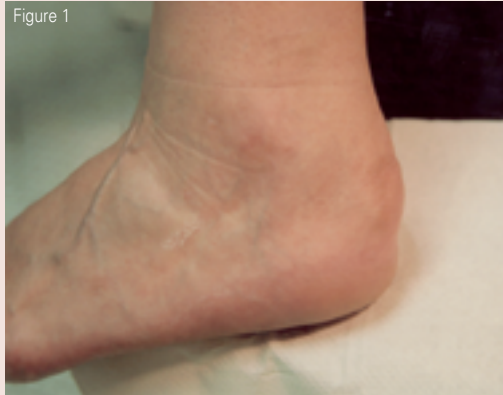

Figure 2



**Question 1**

What is the most likely diagnosis and what commonly causes this problem?

**Question 2**

Betty had an X-ray performed (*Figure 2*). What does it show?

**Question 3**

What treatment would you suggest for Betty?

**ANSWERS TO APRIL BRAIN TEASER**

**Answer 1**

MRI showed a lesion in the lateral segment of the left lobe of the liver. There is a strong suggestion of pseudocapsule.

**Answer 2**

Hepatocellular carcinoma.

**Answer 3**

Hepatocellular carcinoma is curable by surgery only if the tumour is small. The patient had no symptoms or signs of cirrhosis and portal hypertension. He had small solitary nodule without vascular or distant metastases and he underwent surgical resection of tumour.

